

The Application Value of Fractal Analysis Method in the Diagnosis of Benign and Malignant Breast Tumors

Liu Yanan, Li Jingyu, Hao Ligu, Xu Dongbing, Zhao Tianyu, Zou He

Qiqihar Medical University Medical Technology School, the City of Qiqihar,
Heilongjiang Province, Jianhua District, 161006, China

Keywords: Tumor of breast; Differentiation of benign and malignant; Fractal analysis; Application; Value

Abstract: Objective: Studying the value of fractal analysis method in the diagnosis of benign and malignant breast tumors. Method: 76 cases of patients with breast tumor in our department received from January 2016 to January 2018 are the research objects. Among them, 38 patients are patients of breast cancer, and 38 patients are fibroadenoma of breast. Patients of breast cancer are used as the observation group, and patients of breast fibroadenoma are used as the control group. Based on the fractal characteristics of the tumor morphological structure, the fractal method is used to introduce the fractal dimension into the identification of benign and malignant of breast tumors as an indicator. Two groups of images were preprocessed by MATLAB software to extract tumor boundaries. According to the fractal analysis function of Fraclab toolbox, the fractal dimension of some focus is calculated. The fractal dimension values of the images of the focus in the two groups of patients are calculated and compared. The ROC curve based on the fractal dimension value criteria to identify the sensitivity and the specificity of benign and malignant breast tumors is observed and analyzed. Results: In the mean value of the fractal dimension of the ultrasound focus image, the patients in the observation group were significantly higher than the patients in the control group ($P < 0.05$), and the difference between the two groups is significant. Based on the ROC curve, when using the fractal dimension value 1.90 as the threshold value, and the detecting sensitivity and specificity are both high. Conclusion: The difference of fractal dimension of ultrasound images between benign breast tumors and malignant tumors is obvious. And fractal analysis method is feasible in the differential diagnosis of benign and malignant breast tumors. When the fractal dimension value 1.90 is used as the threshold value, the detecting sensitivity and specificity are both high. The fractal analysis method is of great application value in the differentiation of benign and malignant breast tumors.

1. Introduction

On present world-wide scale, breast cancer has become a major public health problem. Since the end of the 1970s, the incidence has increased year by year. Although China is not a country with high breast cancer, in recent years, the growth rate of breast cancer has been 1-2 percentage points higher than that of developed countries. Among the total number of female malignant tumors, the incidence of breast cancer accounts for about 21%, which has become an important threat to women's health. ^[1] Finding and treating it earlier are important in reducing breast cancer mortality. The current diagnosis of breast cancer is mainly the imaging examination. And ultrasound diagnosis is currently the more common method. However, ultrasound diagnosis is subjective and closely related to the physician's clinical experience. How to effectively identify the benign and malignant of breast tumors will directly affect the treatment and prognosis of breast cancer. ^[2] In recent years, with the advancement of medical technology, image quantitative analysis has been introduced into the basic research of tumors to evaluate the growth and diffusion characteristics of different types of tumors. The fractal analysis method has also been gradually applied to the medical imaging analysis of breast tumors, and has played an effective auxiliary role in the differential diagnosis of breast tumors. ^[3] Based on the patients in our department, this paper studies the application value of fractal

analysis methods in the differential diagnosis of benign and malignant of breast tumors.

2. Materials and Methods

2.1. General materials

76 cases of breast tumor patients our department received from January 2016 to January 2018 are the research objects. Among them, 38 patients are patients of breast cancer, and 38 patients are fibroadenoma of breast. Patients of breast cancer are used as the observation group, and patients of breast fibroadenoma are used as the control group. All clinical, imaging and pathological data of the patients are collated. All patients were confirmed by pathological examination to be breast cancer or breast fibroma. The patients in the observation group are 31-72 years old and with an average age of 45.3 ± 4.2 years old. The patients in the control group are 30-73 years old and with an average age of 44.9 ± 4.8 years old. None of the patients in the two groups had received any anti-tumor treatment.

2.2. Methods

2.2.1. Method of examination

Both groups of subjects undergo routine ultrasound examination within one week prior to biopsy. All patients were examined independently by the same sonographer. Hitachi color Doppler ultrasound imaging system is used. Set the probe frequency to 5-10MHz, and scan the various sections of the patient's mammary gland. At the same time, pay attention to the characteristics of the tumor area and access the clear image.

2.2.2. Image processing method

The acquired images were pre-processed by MATLAB software, and the tumor regions were cut out by segmentation and localization to calculate the fractal dimension parameters of the focus. The tumor images of both groups are enhanced by 256 gray scale values and optimized contrast values to ensure that the image analysis conditions are basically the same and the results are well comparable. Both sets of tumor images were converted into matrix data format to facilitate various calculations. When selecting the analysis area, it is necessary to ensure that the intercepted area can contain all the tumor boundaries and minimize the interference of non-tumor tissues. After grayscale transformation, image binarization, image inversion and morphological processing, both groups of patients finally can get satisfactory images that could be analyzed by fractal analysis.

2.2.3. Fractal analysis method

The fractal dimension of target area is calculated by using one-dimensional difference box counting method. Importing the preprocessed images into the Fraclab toolbox. By choosing the differential box counting method, the double logarithmic coordinates of fractal analysis of breast cancer images can be obtained. According to this result, the slope is the fractal dimension of the breast tumor. As shown in Figure 1 below.

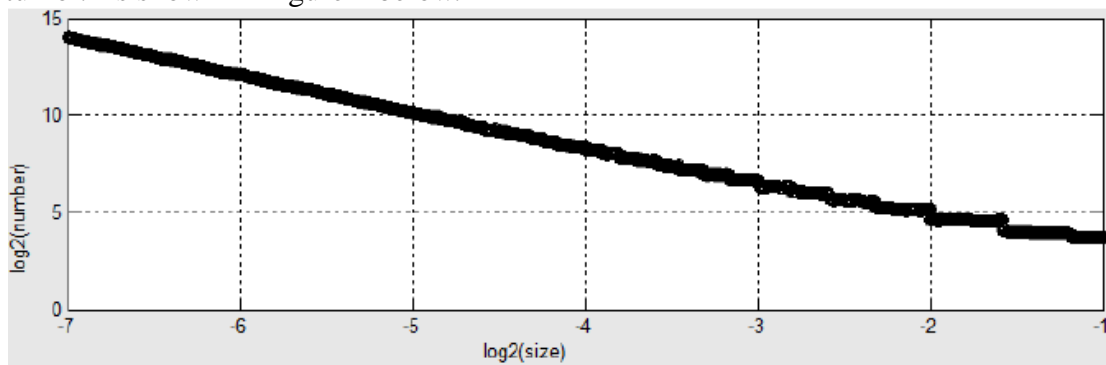


Figure 1 Double logarithmic graph in differential box counting method. Where the slope of the line is the fractal dimension of the image

2.3. Observation indicator

Calculating and comparing the fractal dimension values of the images of some focus in the two groups of patients. Observing and analyzing the ROC curve to identify the sensitivity and specificity of the benign and malignant of breast tumors based on the fractal dimension value criteria.

2.4. Statistical processing

Statistical processing software SPSS19.0 is used to analyze the data of various indicators of patients. The t test was used for comparison between groups, and the statistical significance is on $P < 0.05$. In order to more accurately define the value of identifying breast cancer through ultrasound assisted with fractal dimension as indicators, the ROC analysis method is used.

3. Results

3.1. Comparison of fractal dimension values of partial images of focus in two groups of patients

In the mean value of the fractal dimension of the ultrasound image, the value of the patients in the observation group were significantly higher than it of the control group ($P < 0.05$), and the difference between the two groups is significant. See Table 1 for details.

Table 1 Comparative analysis of fractal dimension values of focus images in two groups of patients (points)

Groups	Cases(n)	Fractal dimension value
Observation group	38	1.95±0.02
Control group	38	1.92±0.03
t		3.21
P		<0.05

3.2. The ROC curve is shown in Figure 2 below.

According to Figure 1, the area under curve is 0.94, and P is 0.02, which is statistically significant, indicating that the fractal dimension has diagnostic significance on breast cancer ultrasound images. Based on the ROC curve, when the fractal dimension value 1.90 is used as the threshold value, the detecting sensitivity and specificity are both great.

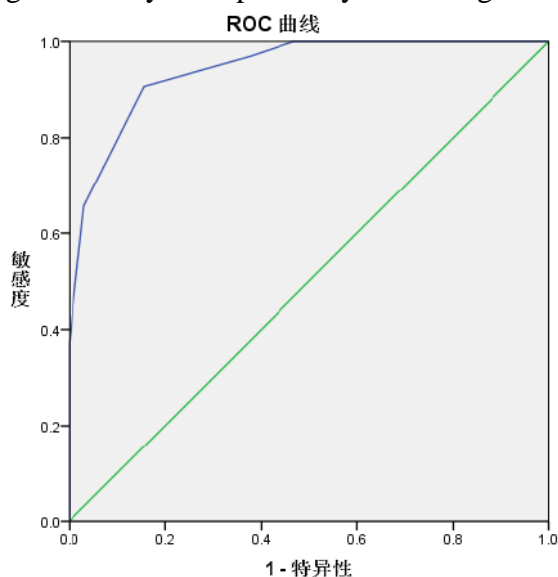


Figure 2 ROC curve for differential diagnosis of benign and malignant of breast tumors based on fractal dimension criteria

4. Discussion

Although the incidence of breast cancer in the worldwide has increased year by year, the mortality rate has decreased year by year. The current 10-year survival rate of women with ≤ 1 cm invasive breast cancer can reach about 95%. The reduction in mortality is mainly related to the continuous improvement of the diagnosis and treatment of breast cancer. However, compared with the 10-year survival rate of women with ≤ 1 cm invasive breast cancer, the 10-year survival rate of 1-2cm invasive breast cancer is 82%, and the 10-year survival rate of 2-5cm invasive breast cancer is 60%. Therefore, early diagnosis plays an important role in the prognosis of breast cancer.^[4]

The diagnosis of breast cancer in China is mainly the breast ultrasound detection. Breast ultrasound examination is not only timely, but also accurate in describing the size, location and overall shape of the tumors. However, ultrasound imaging is greatly affected by ultrasound operation techniques and examination time, which leads to some limitations in the identification of benign and malignant of the breast tumors.^[6] Therefore, due to the lack of a unified standard of objective data specifications, different diagnostic results may occur in the diagnosis of the same case. In recent years, the application of fractal geometry in medical image texture recognition has become increasingly widespread. The fractal dimension is a quantitative parameter, which has a good application value in medical image texture recognition.^[6] The graphics in nature mainly exist in the form of graphics with feature length and graphics with no feature length. Each position of a graph with characteristic length can be differentiated. Graphics without feature length can be studied by fractal dimension. An ultrasound image of a breast tumor is an image that is of no characteristic length. Therefore, some researchers have proposed to apply the fractal analysis method to the ultrasound image of breast tumors, so that the fractal dimension value becomes an ultrasonic examination measurement indicator, thus more objectively assisting the ultrasound diagnosis in breast cancer.^[7] Foreign studies have confirmed that the morphology of tumors can be studied using fractal theory.^[8]

In this study, the MATLAB software is used to perform pre-processing and fractal analysis on the ultrasound images of both groups of patients. MATLAB is widely used in scientific and engineering calculations. It can perform not only matrix operations, but also numerical analysis and graphic processing. It is very powerful.^[9] The boundary of the ultrasound image is affected by many factors, and it is not clear, so it is now converted to gray scale. Then, the image is binarized to eliminate the blurred image, and the target image is highlighted. After grayscale transformation, image binarization, image inversion and morphological processing, the two groups of patients finally got satisfactory images that can be analyzed by fractal analysis, and then importing them into Fraclab toolbox. The fractal dimension of the ultrasound image of the breast tumor can be calculated by Fraclab.^[10] The results of the study shows that the fractal dimension value of observation group is 1.95 ± 0.02 , and the control group has a fractal dimension value of 1.92 ± 0.03 . The patients in the observation group are significantly higher than the patients in the control group ($P < 0.05$) in the mean value of the fractal dimension value of the ultrasound image focus, and the difference between the two groups is significant. And Based on, when the fractal dimension value 1.90 of the ROC curve is used as the threshold value, the detecting sensitivity and specificity are both greater. It can be seen that the fractal dimension value has diagnostic significance in breast cancer ultrasound images.

5. Conclusion

In summary, the difference in the fractal dimension between the benign breast tumor and the malignant tumor is obvious, indicating that the fractal analysis method is feasible in the identification of benign and malignant of breast tumors. When the fractal dimension value 1.90 is used as the threshold value, the detecting sensitivity and specificity are both greater. This indicates that the fractal analysis method is of great application value in the differential diagnosis of benign and malignant of breast tumors, and it deserves to be clinically applied.

Acknowledgments

The Qiqihar science and Technology Bureau Foundation of China under (Grant No. GYGG-201712) “Research on Regional Localization and Classification of Breast Tumor base on ultrasonoscopy”.

References

- [1] Wanzhi Song, Jinnan Gao, Haibo Yang. Epidemiological state and characteristics of breast cancer [J]. Chinese Remedies & Clinics, 2017(02):228-229.
- [2] Yu Ji, Li Li, Xiaoxia Hou. Clinical reasearch on color doppler ultrasound in diagnosis of benign and malignant breast lumps andassessing of TNM staging [J]. Shaanxi Medical Journal, 2017(12):1702-1703.
- [3] Yahong Luo. Progresses and research direction of imaging diagnosis of breast cancer [J].Chinese Journal of Medical Imaging Technology, 2017, 33(5): 645-646
- [4] Jin Sh, Di Liang, Daojuan Li. Epidemiological Status of Global Female Breast Cancer [J].China Cancer, 2017(09):683-690.
- [5] Sanqian Huang, Jingmin Zhong, Jing Li. Advances in Breast Cancer Molecular Typing [J]. Progress in Modern Biomedicine, 2016(22) 22: 4384-4387.
- [6] Hongxin Zhang, Peirong Zhao, Dongling Gao, et al. Fractal study on nuclear boundary of breast tumor[J]. JOURNAL OF ZHENGZHOU UNIVERISTY (MEDICAL SCIENCES), 2002(04): 431-433.
- [7] Chen Cheng. Comparative study of MRI, full digital mammography (FFDM) and breast B ultrasound in the diagnosis of breast cancer [J]. Women's Health Research, 2017(04):17-18.
- [8] West CM, Jones T, Price P.The potential of positron-emission tomography to study anticancer-drug resistance[J].Nat Rev Cancer,2004,4(6):457-469.
- [9] Ting Li, Kang'an Li, Yun Xiong. Research progress on computer aided diagnosis of breast cancer [J]. Chinese Journal of Radiology, 2017, 51(11): 887-890.
- [10] Shuxia Bai. The value of digital mammography computer-aided diagnosis on breast cancer detection [J].Image Technology, 2015(06): 9-10.